



Adult Colo - Colonic Intussusception caused by Lipoma: A Case Report



CHRYSMEISIS D.R. HUERTO, MD

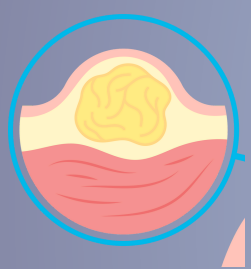
SHERWIN S. ALAMO, MD, FPCS, FPSCRS, BRENT G. VIRAY, MD

General Emilio Aguinaldo Memorial Hospital, Trece Martires City, Philippines

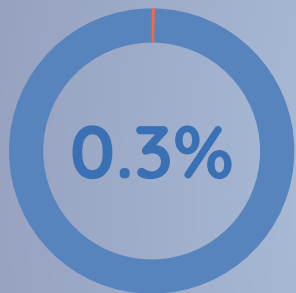

INTRODUCTION


Colonic Lipoma



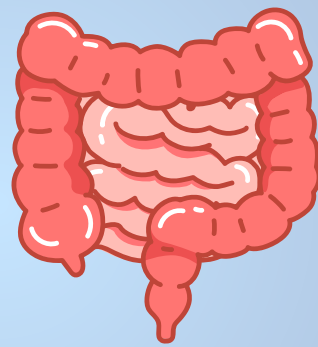
Benign epithelial tumor



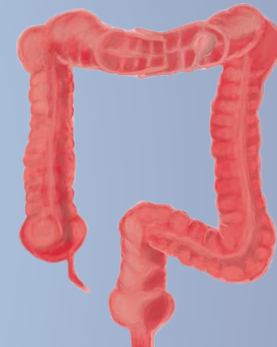Incidence rate worldwide



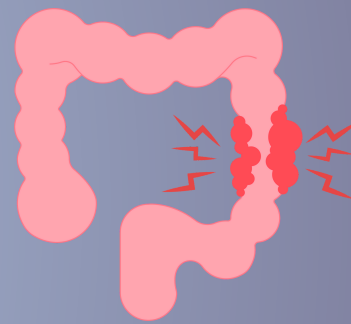
Common in Cecum and Ascending colon



Asymptomatic <2cm



Symptomatic >5cm




Intussusception Obstruction

CASE



44/F



Vomiting



Palpable Mass Left Hemiabdomen

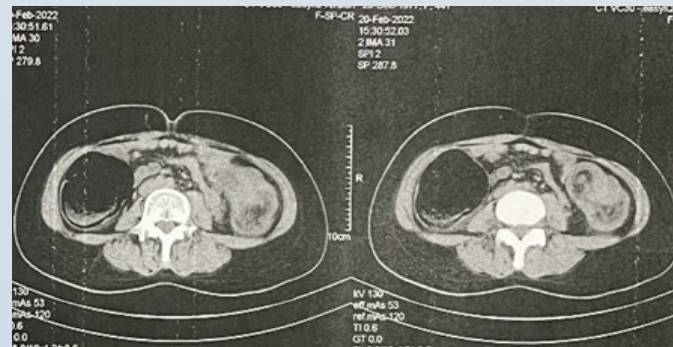


Abdominal Pain



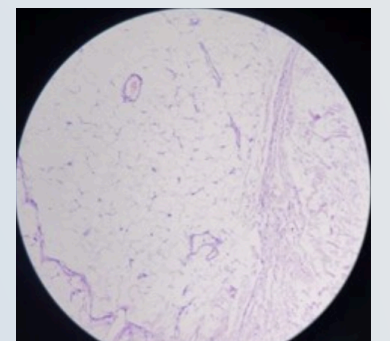
Mucoid/ Bloody Stools

Imaging



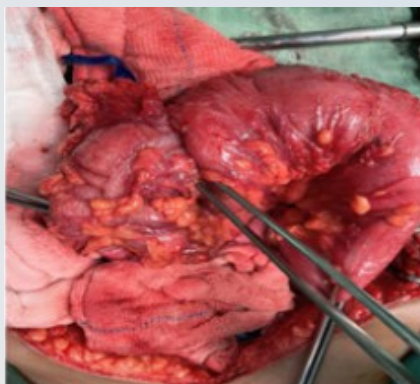
Computed Tomography with contrast revealing a colo-colic intussusception of the distal transverse colon (intussusceptum) and proximal descending colon (intussuscepiens) due to a intraluminal mass causing partial obstruction. Yellow arrow showing the classic "target sign"

Histopathology

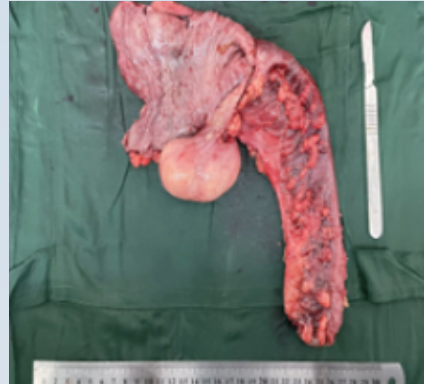

Non-neoplastic colonic epithelium with mature fatty tissue of the lipoma underneath.

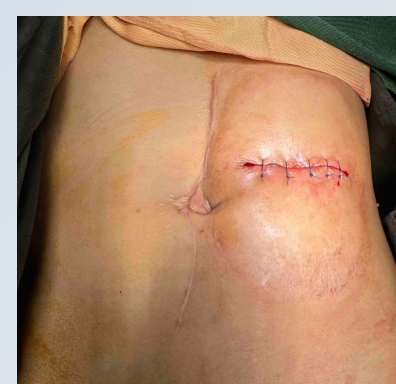Exploratory Laparotomy, Left Hemicolectomy w/ Double Barrel Colostomy



Invagination of mid to distal transverse colon to the proximal descending colon causing obstruction



Colonic Lipoma at splenic flexure

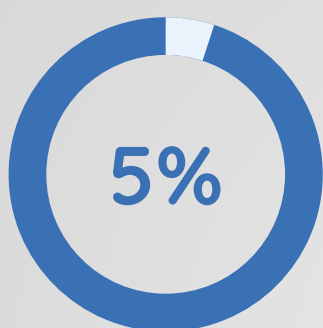


Closure of Colostomy

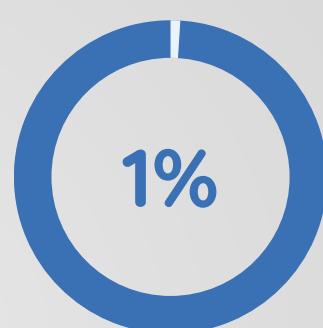
KEY POINTS

1:1300

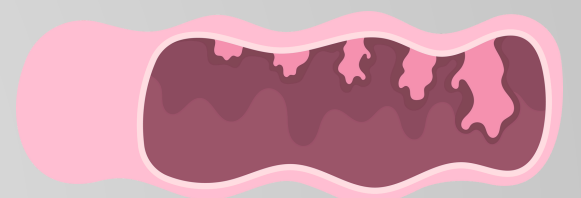
Abdominal Operations



Adults



Bowel Obstruction



Tumor MC cause

Colonic Lipoma causing intussusception is a rare surgical entity. Thorough History taking, Physical examination and proper use of Diagnostics are vital in diagnosis of this case.