

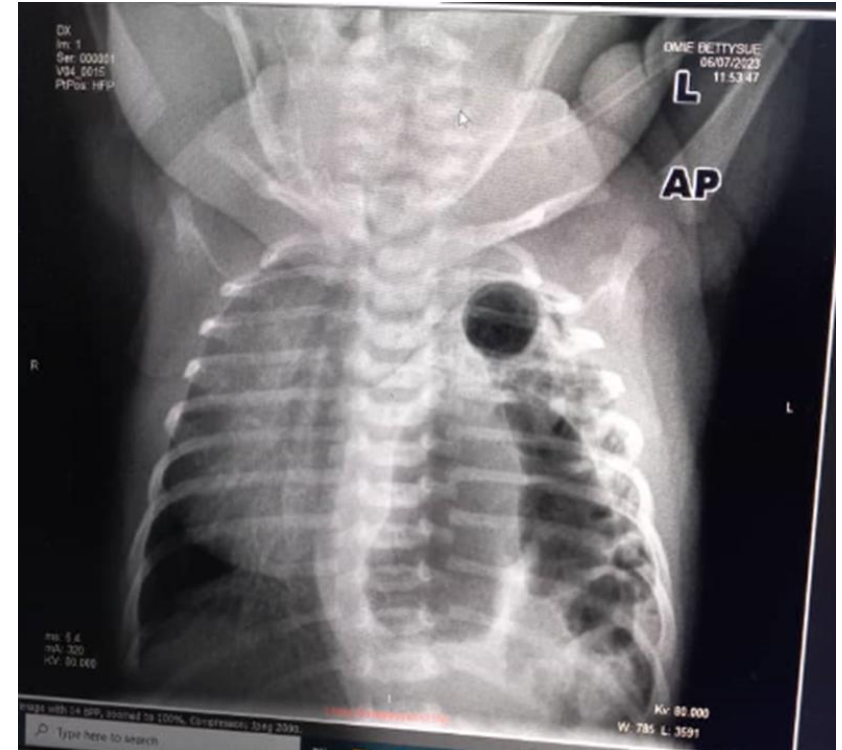
Congenital diaphragmatic hernia management in a provincial hospital of Papua New Guinea: A case report of challenges in a non-neonatal intensive care setting

Ian Umo, Rodger Ikasa, Kennedy James

Alotau Provincial Hospital, Milne Bay Provincial Health Authority

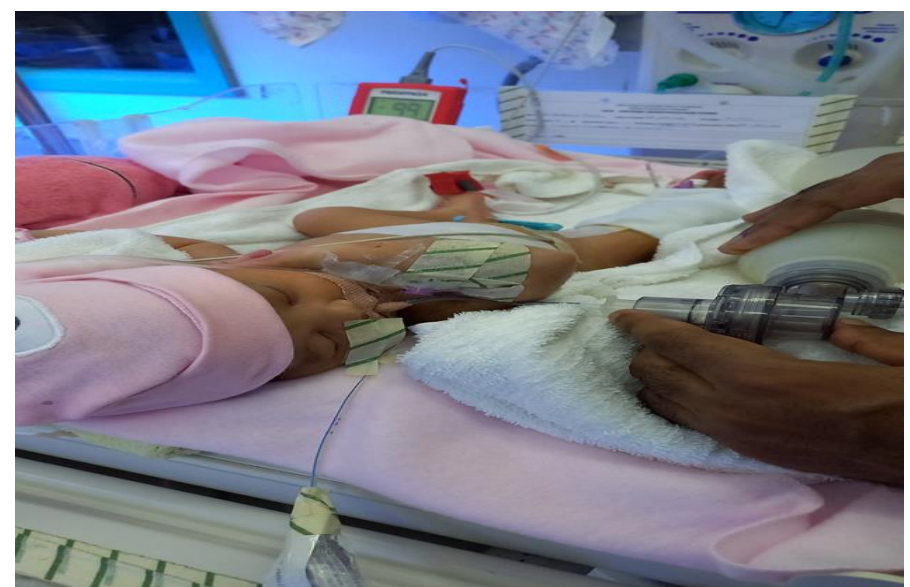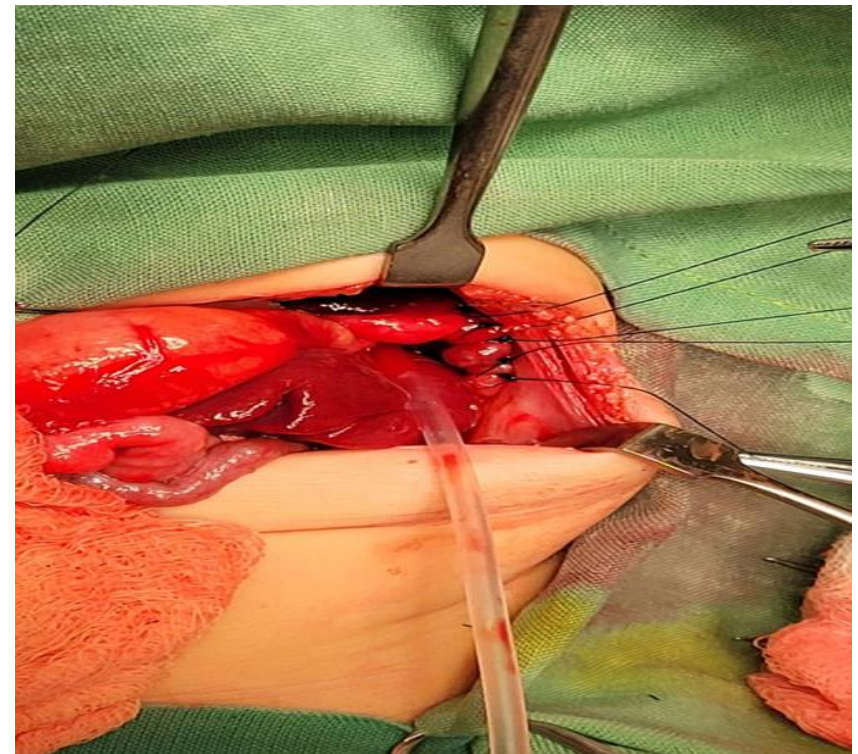
Introduction

- ❑ Management of CDH can be challenging in a provincial hospital where diagnostic, supportive and definitive services are limited.
- ❑ This case report highlights challenges of CDH management in a non neonatal intensive care setting.



Case report

- ❑ A female baby who developed cyanosis and grunting two hours after birth was seen by the surgical team.
- ❑ Surgery was performed when the neonate's condition and hemodynamic parameters were stabilized for at least twenty-four hours.
- ❑ Left posteriolateral diaphragmatic hernia: 3cm x 4cm
- ❑ Herniated contents included: Stomach, spleen, transverse colon and Ileum
- ❑ Post-operative manual ventilation and subsequent extubation were successful.



Case report

- ❑ Management of CDH is multidisciplinary.
- ❑ Many challenges faced in managing such cases in a provincial hospital.
- ❑ Communication is important.
- ❑ Good clinical, timely intervention is paramount.

